



# Apples Aren't Always Apples

Robert Marks, M.D., Hiep Tran, M.D., Miles Day, M.D.

# Low Back Pain: Initial Evaluation

*54 year old Female with no significant past medical history...*

## Subjective

- Continuous Back Pain
  - Dull
  - NRS 2-6/10
- Onset 3 Years Prior
  - Fall → Land on tailbone
- Radiates to Left Leg
- Alleviating Factors
  - Minimize stress on left leg

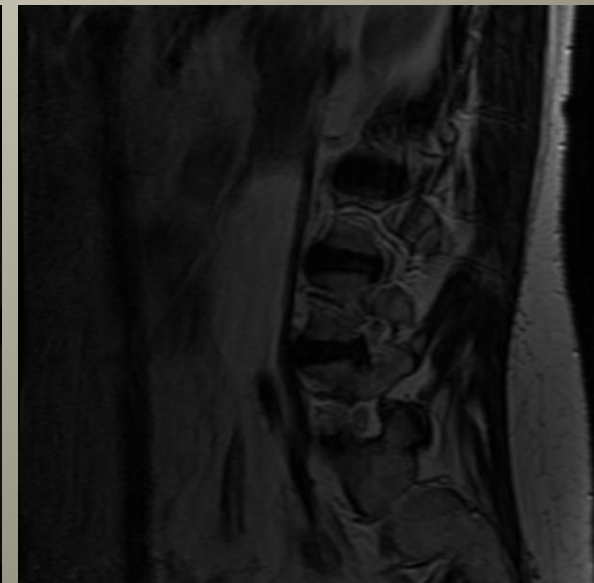
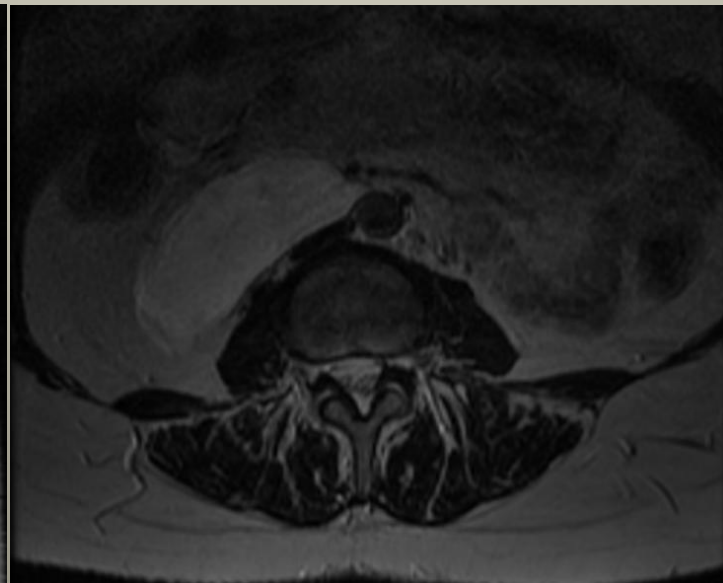
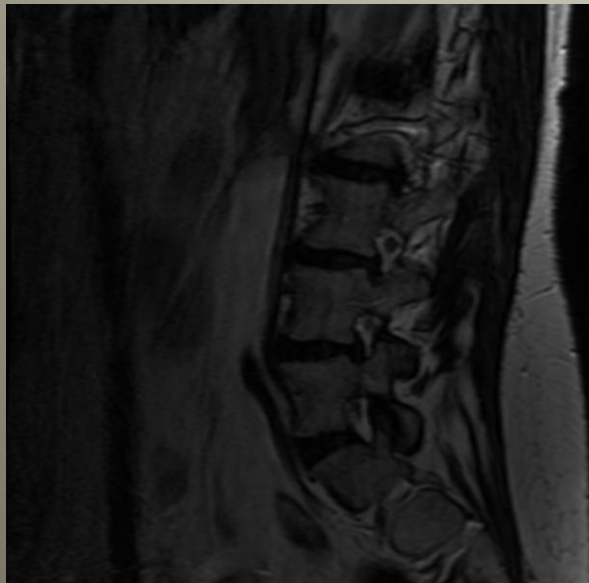
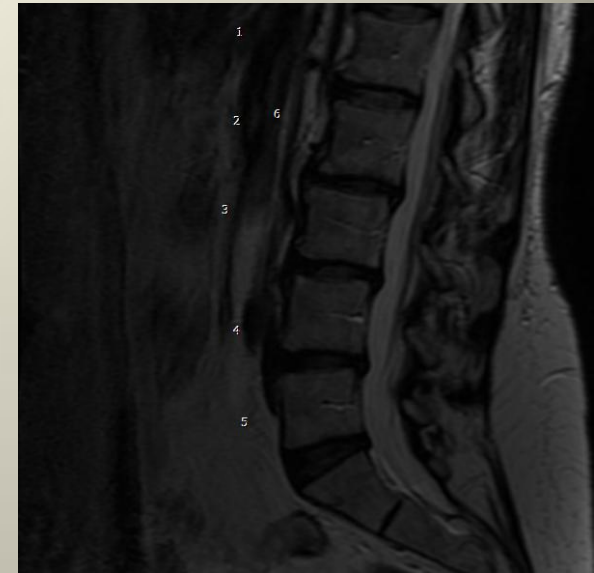
## Objective

- Straight Leg Raise
  - Left: + at 50 Degrees
- Left FABER
- Left Kemp's

# MRI Lumbar Spine (1/14/2004)

## Report

- Diffuse Spondylosis
- Diffuse DDD
- Scoliosis
- Disc Bulge at L3-4 & L4-5
  - Associated with Foraminal Stenosis



# Caudal Lysis of Adhesions

*Relief for ten months*

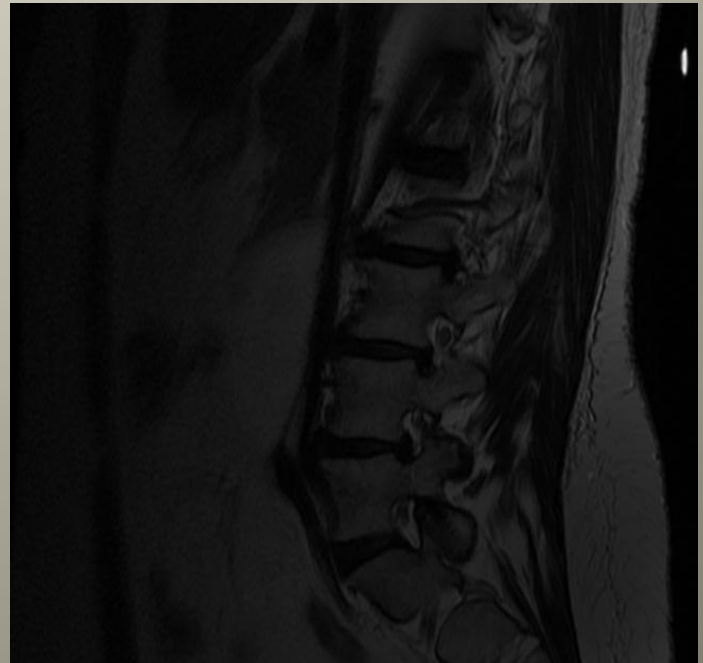
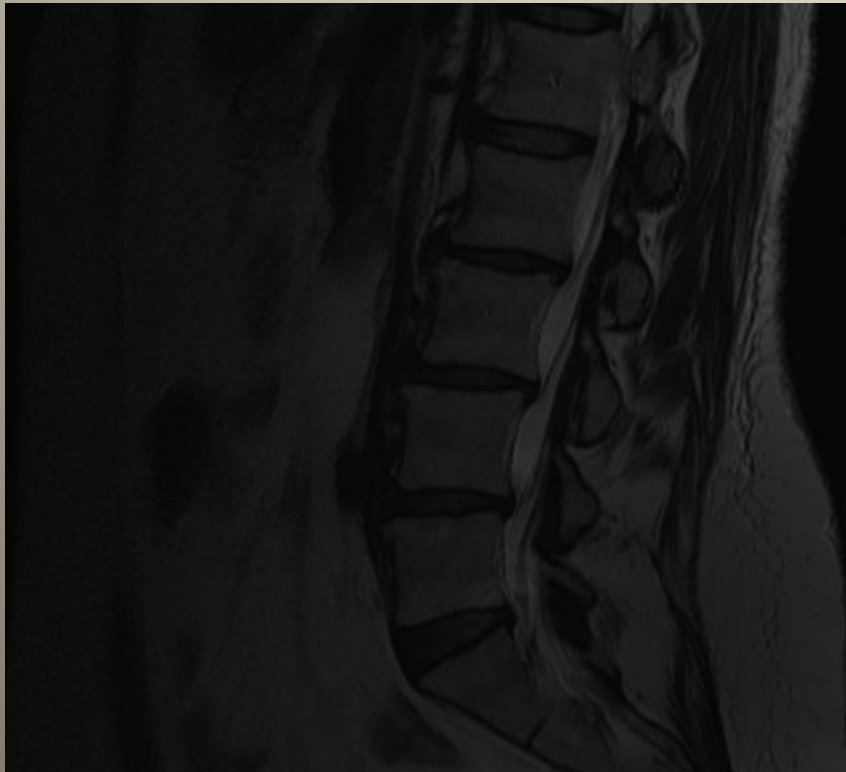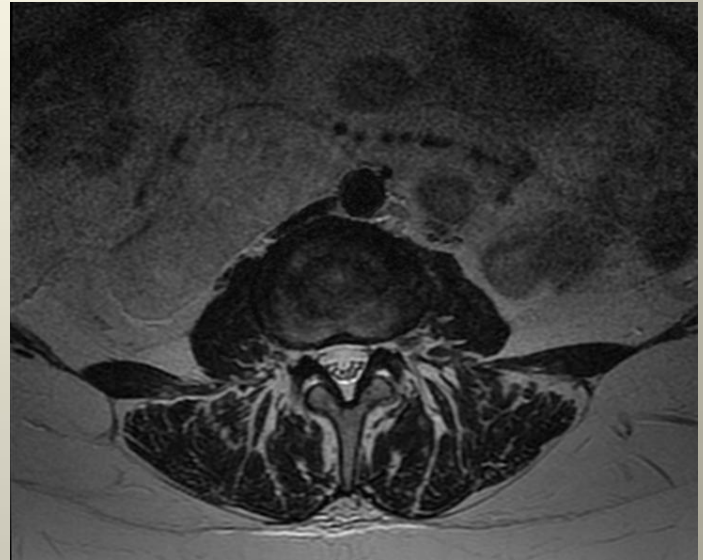
**Returned to clinic:** Exact same symptoms

- Aching low back pain
- Intermittent radiation to left leg and ankle
- Left Leg: Subjective weakness & dysesthesia
- No bowel or bladder issues

# MRI Lumbar Spine (1/8/2005)

## Report

- Mild diffuse disc bulge
- Bilateral recess stenosis at most levels



# Caudal Lysis of Adhesions

*Relief for 1 year*

## **Returned to clinic 17 months later:**

### – Subjective

- Pain now burning in quality
- Left low back & radiates to left posterior calf
- No bowel or bladder issues

### – Objective

- Gained 16 pounds
- Positive Left SLR, Kemp, SI Joint Tenderness

# Transforaminal Epidural Steroid x3

*Relief for over a year*

## **Returned to clinic sixteen months later:**

### – Subjective

- Pain: Left buttock, Left hip, Left lateral thigh radiating down her leg to her ankle
- No bowel or bladder symptoms or weight change

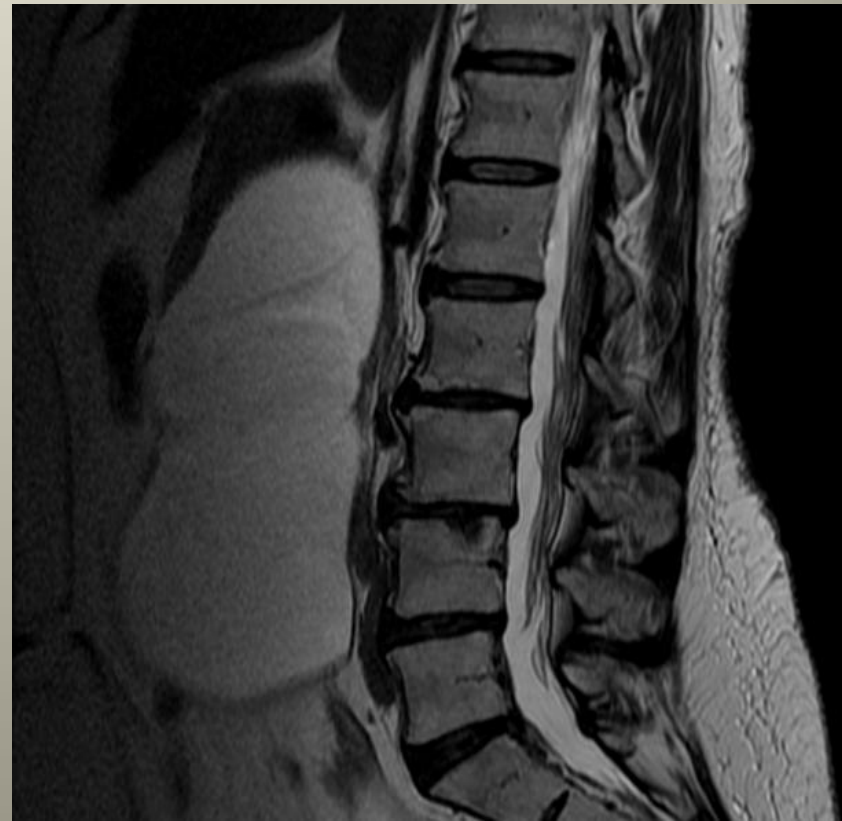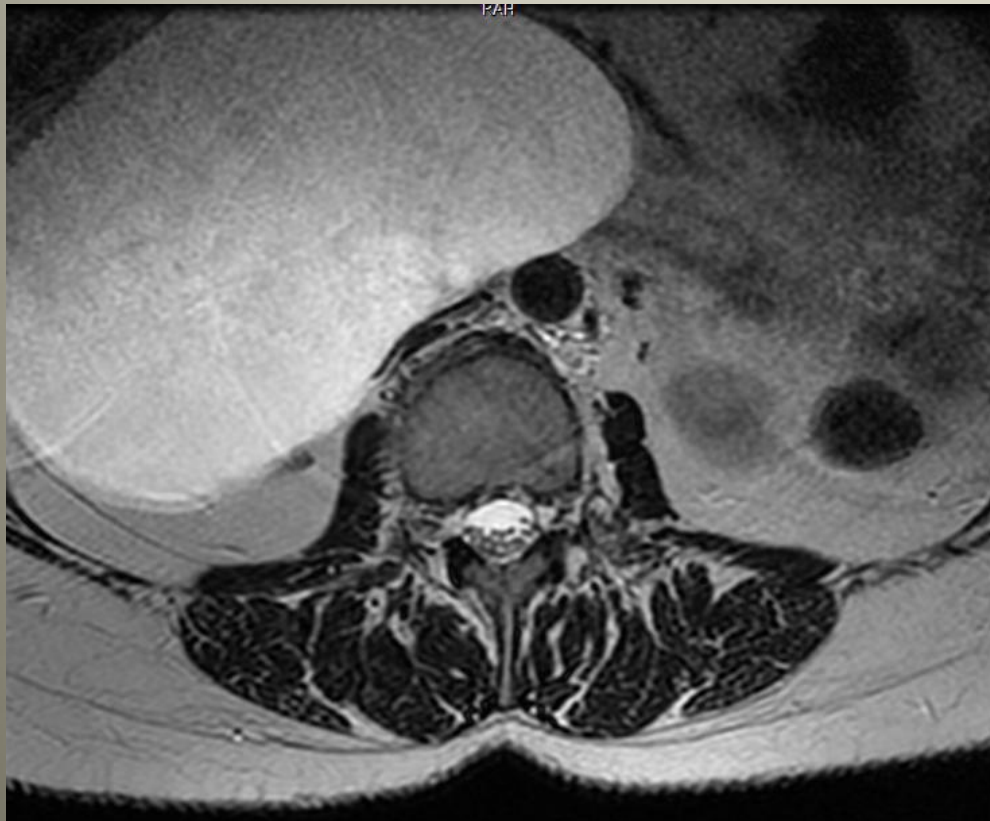
### – Objective

- Kemp, SI Joint Tenderness
- Negative SLR bilaterally

# MRI Lumbar Spine (2/26/2008)

## Report

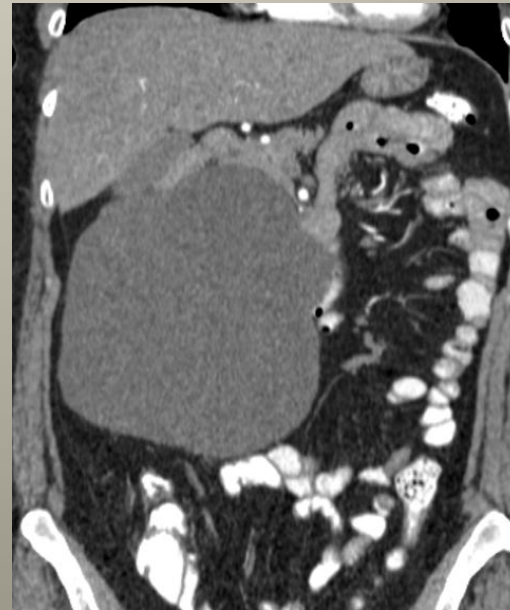
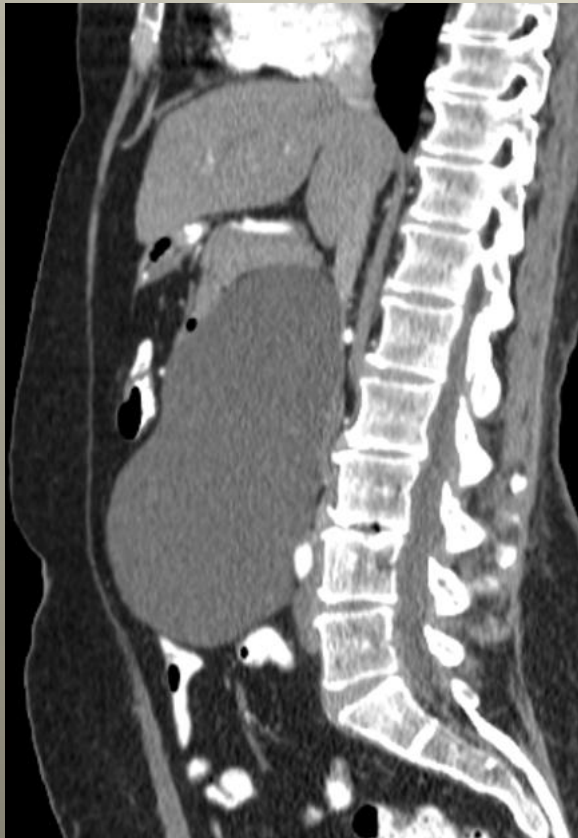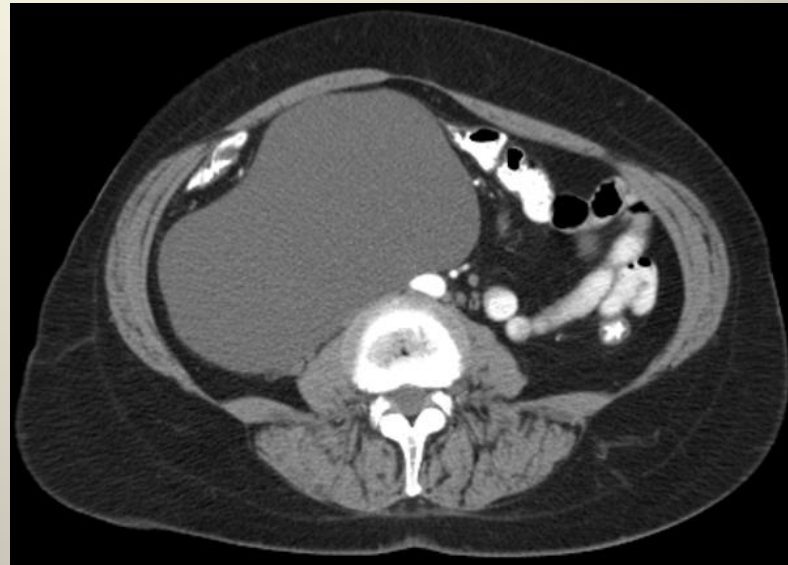- DDD mildly advanced since 2005
- Mild bilateral foraminal stenosis L5/S1
- 18 x 9 x 14 cm mass on right side of abdomen



# CT Abdomen & Pelvis (2/29/2008)

## Report

- Cystic mass right side of abdomen
  - 17.7 x 10.5 x 15.2 cm
  - Abuts small bowel, pancreatic head, uncinete process, right kidney



# Clinical Course

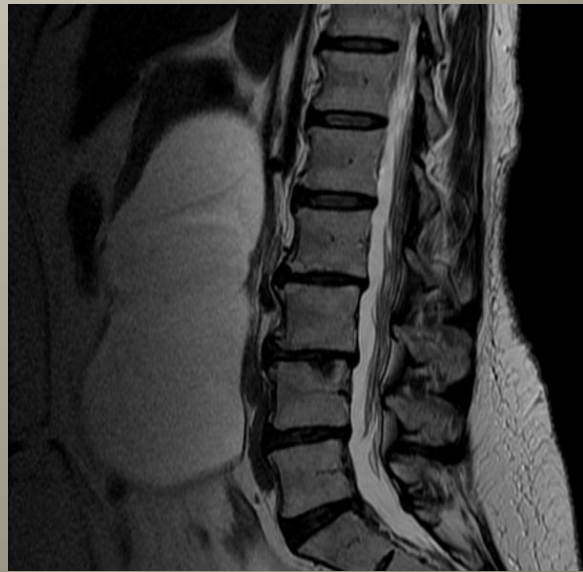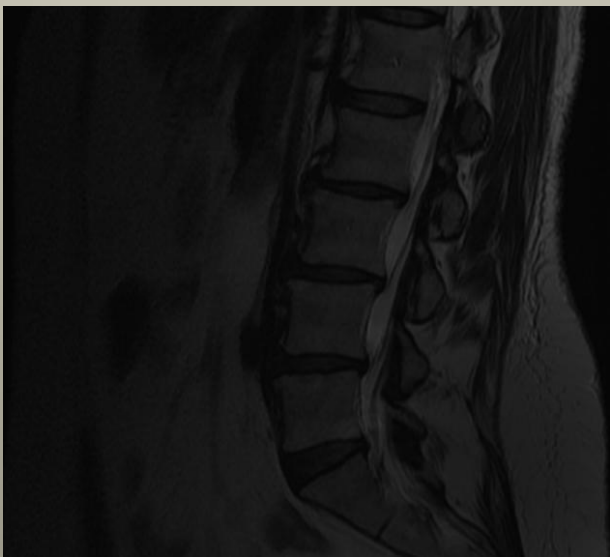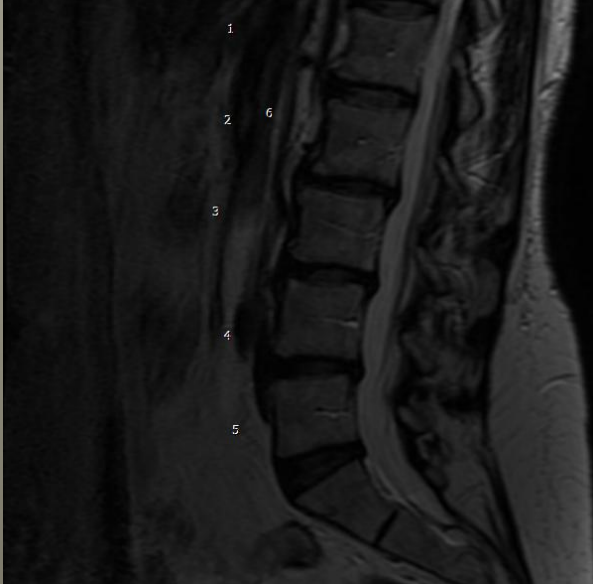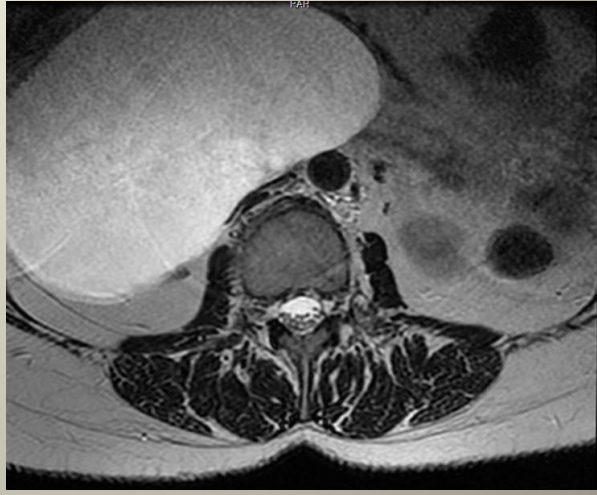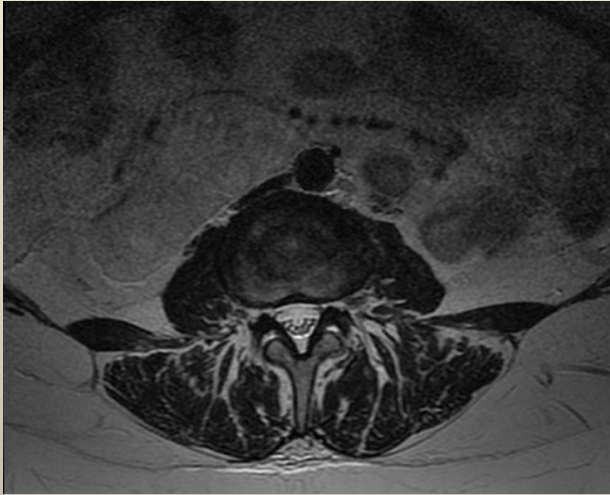
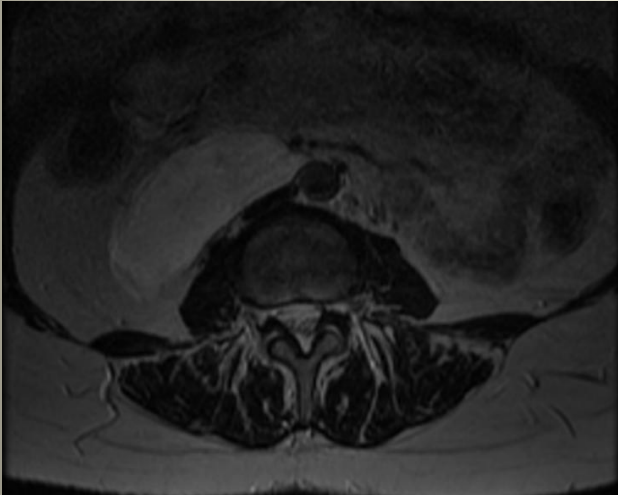
- Resection: 3/11/2008
  - Lymphangioma
    - 15 x 15 x 2.5 cm
    - Weight: 460 grams full; 42.3 grams drained
    - Leaking yellow fluid
  
- Back & Leg pain RESOLVED

# Look Again

2004

2005

2008



# References

- Lurie JD, Gerber PD, Sox H. A Pain In The Back. The New England Journal of Medicine 2000, 343-10:723-726.
- Perrot M, Rostan O, Morel P. Abdominal Lymphangioma in Adults and Children. British Journal of Surgery 1998, 85:395-397.
- Guinier D, Denué P, Manton G. Intra-abdominal Cystic Lymphangioma. The American Journal of Surgery 2006, 191:706-707.